


100 Essential Cases in Orthopaedics and Rheumatology: An Anatomical and Imaging-Based Approach

Overview

100 Essential Cases in Orthopaedics and Rheumatology is a unique and comprehensive collection of orthopaedic and rheumatology cases, presented in a highly visual and engaging format. Each case includes high-quality images, detailed descriptions, and expert analysis, providing a thorough understanding of the clinical presentation, diagnosis, and management of common orthopaedic and rheumatologic conditions.

This book is an invaluable resource for students, residents, and practicing physicians in orthopaedics, rheumatology, and related fields. It is also an excellent resource for self-study and continuing medical education.



100 Cases in Orthopaedics and Rheumatology

by Juliana Magalhães

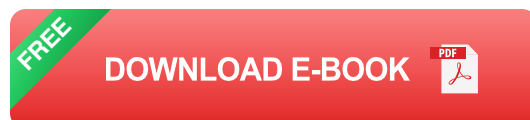★★★★☆ 4.4 out of 5

Language : English

File size : 9350 KB

Print length : 288 pages

Screen Reader : Supported



Features

- 100 essential cases in orthopaedics and rheumatology

- High-quality images and detailed descriptions
- Expert analysis and management advice
- Covers a wide range of orthopaedic and rheumatologic conditions
- Ideal for students, residents, and practicing physicians
- Excellent resource for self-study and continuing medical education

Table of Contents

- **Section 1: Upper Extremity**
 - Shoulder Pain
 - Elbow Pain
 - Wrist Pain
 - Hand Pain
- **Section 2: Lower Extremity**
 - Hip Pain
 - Knee Pain
 - Ankle Pain
 - Foot Pain
- **Section 3: Spine**
 - Neck Pain
 - Back Pain
 - Sciatica

- **Section 4: Rheumatology**

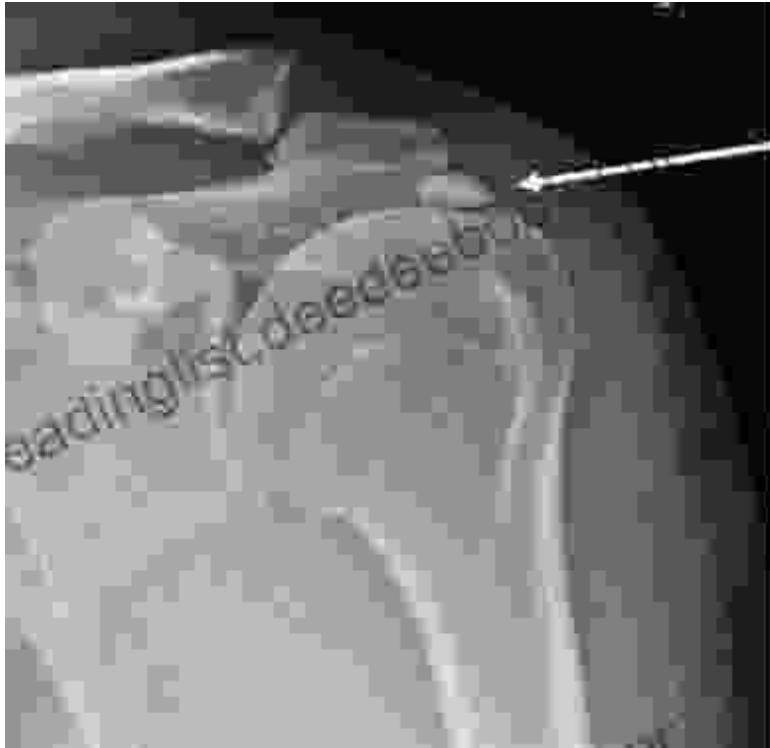- Arthritis
- Osteoporosis
- Fibromyalgia
- Gout

Sample Case

Case 1: Shoulder Pain

A 45-year-old male presents with a 6-month history of right shoulder pain. The pain is worse with overhead activities and at night. He has no history of trauma or recent falls. Physical examination reveals tenderness to palpation over the greater tuberosity of the humerus. Range of motion is full and pain-free in all directions. There is no crepitus or instability.

Imaging: X-ray of the right shoulder shows a small calcific deposit in the supraspinatus tendon.




Plain X-Ray
demonstrating a
calcific deposit
within the
Supraspinatus
Tendon

X-ray of the right shoulder showing a small calcific deposit in the supraspinatus tendon

Diagnosis: Calcific tendinitis of the supraspinatus tendon

Management: Conservative treatment with rest, ice, and physical therapy is usually sufficient to relieve symptoms. In some cases, corticosteroid injections may be helpful. Surgery is rarely necessary.

100 Essential Cases in Orthopaedics and Rheumatology is a valuable resource for anyone involved in the diagnosis and management of orthopaedic and rheumatologic conditions. The book's unique and comprehensive format makes it an ideal resource for students, residents, and practicing physicians. It is also an excellent resource for self-study and continuing medical education.



100 Cases in Orthopaedics and Rheumatology

by Juliana Magalhães

★★★★☆ 4.4 out of 5

Language : English

File size : 9350 KB

Print length : 288 pages

Screen Reader : Supported



Unveiling Hidden Crete: A Comprehensive Review of Richard Clark's Notebook

In the tapestry of travel literature, Richard Clark's 'Hidden Crete Notebook' stands as a vibrant thread, inviting readers to unravel the enigmatic beauty of the Greek...



New Addition Subtraction Games Flashcards For Ages Year

Looking for a fun and educational way to help your child learn addition and subtraction? Check out our new addition subtraction games flashcards...